大脳の動脈（上から）

Before

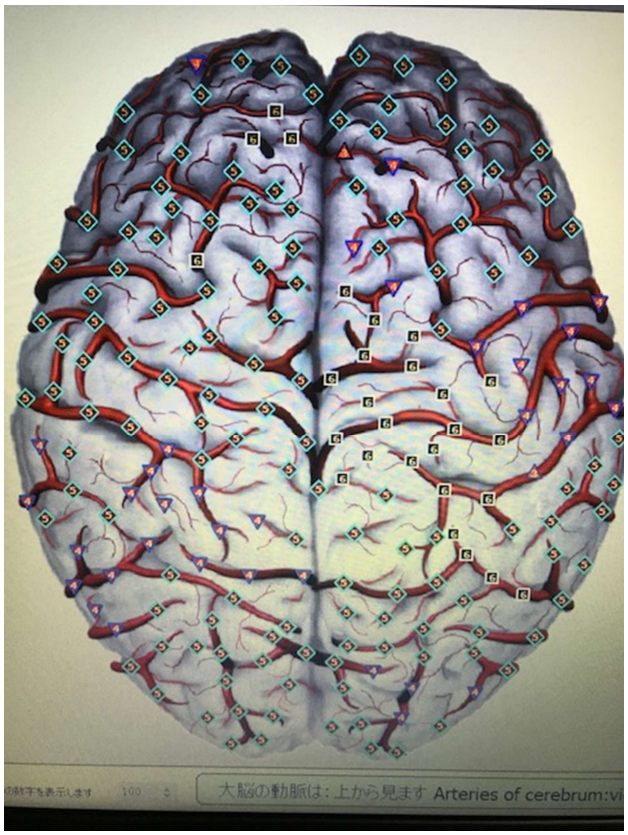
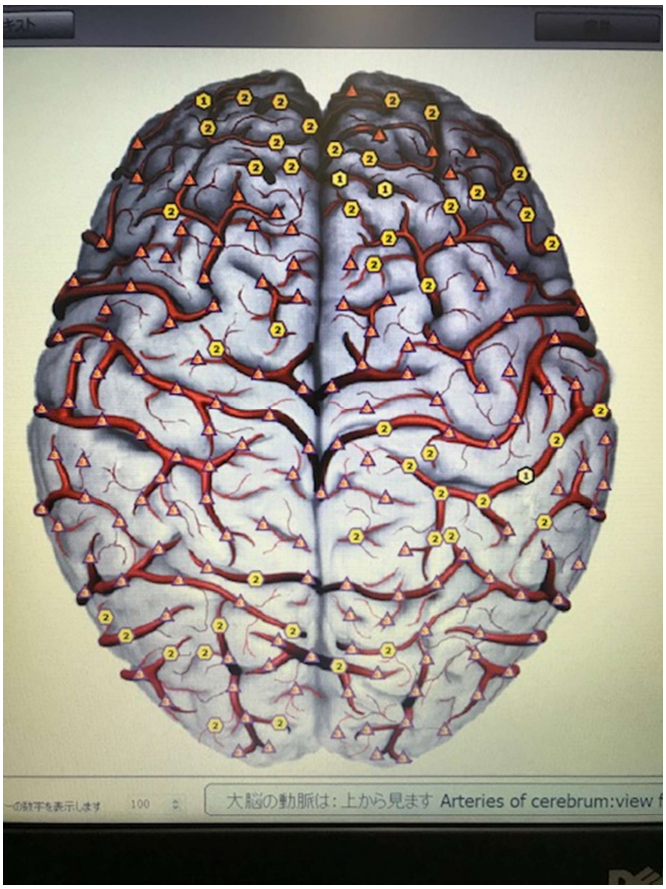
After